



PATIENT

Paige Parker

PRESENTING CLINICAL SIGNS

History: Coughing during exertion. Grade 2/6 heart murmur.

SPECIES

Canine

RADIOGRAPHIC FINDINGS *NOTE: Images submitted for supplemental cardiac information only.

Normal cardiac silhouette. No obvious evidence of CHF.

BREED

Mix

ECHOCARDIOGRAM FINDINGS

2D, m-mode, color flow and doppler imaging is available. Mild mitral valve thickening with no prolapse into the left atrial lumen. No mitral regurgitation; normal left atrial dimension. Normal LV diameter with normal myocardial function. The tricuspid valve appears normal in form and function. Normal right atrial and ventricular diameter and morphology indicating no overt evidence of pulmonary arterial hypertension. The pulmonic and aortic valves are normal in morphology and mobility. Normal Ao/LVOT and PA/RVOT velocity. No aortic or pulmonic insufficiency. No pericardial or pleural effusion noted. No obvious cardiac tumors seen.

AGE

6 years

CARDIAC CHART

WEIGHT

35lbs

CANINE CARDIAC PARAMETERS	MR VMAX (m/s)	TR VMAX (m/s)	LA/AO (Boon method)	LA/AO (Heart Base; Swe)	FS (%)	EF (%)	EPSS (cm)
NORMAL PARAMETER	4.5-5.5	<2.7	1.3	<1.6	28-40	40-100	<0.6
PATIENT	NA	NA	NM	1.0	40	70	0.56
CANINE CARDIAC PARAMETERS	HR (BPM)	AV VMAX (m/s)	PV MAX (m/s)	BODY WEIGHT (kg)	LA 2D short axis Base view (cm)	LVIDd Avg; 2D and m-mode short axis (cm)	LVIDs Avg; 2D and m-mode short axis (cm)
NORMAL PARAMETER	50-100	0.7-1.7	0.7-1.6	BELOW	BELOW	BELOW	BELOW
PATIENT	100	1.6	0.5	15.9	1.9	3.8	2.1
*Normal chamber parameters expressed as a mean value (SD)				3	1.27 (5.3)	2.46 (2.46)	1.36 (5.5)
BODY WEIGHT DEPENDENT PARAMETERS				5	1.40 (4.5)	2.74 (5.2)	1.60 (4.7)
<i>*Note: All measurements based upon multi-modal images and methods. An average value is reported.</i>				10	1.50 (3.8)	3.27 (3.5)	2.06 (3.1)
				15	1.83 (2.0)	3.71 (2.4)	2.43 (2.1)
				20	2.02 (1.9)	4.14 (2.2)	2.80 (2.0)
				25	2.18 (2.4)	4.48 (2.9)	3.10 (2.5)
				30	2.33 (3.3)	4.83 (3.9)	3.39 (3.4)
				35	2.48 (4.3)	5.17 (5.0)	3.69 (4.5)
				40	2.62 (5.2)	5.48 (6.1)	3.96 (5.4)
				50	2.88 (7.1)	6.07 (8.3)	4.46 (7.4)

Adapted from June Boon, Veterinary Echocardiography, 1998
 Rishniw M and Hollis NE, J Vet Intern Med 2000; 14:429-435
 Hansson et al, Vet Rad and Ultrasound 2002
 Bonagura et al. Echocardiography: principles of interpretation, Vet Clin North Am 15:1177, 1995

INTERPRETED BY

Maggie Machen Lamy, DVM, DACVIM (Cardiology)

IMAGING PERFORMED BY

Jennifer Snyder, Sand Hills MVU

HOSPITAL NAME

Pine Valley Animal Hospital

REFERRING VET

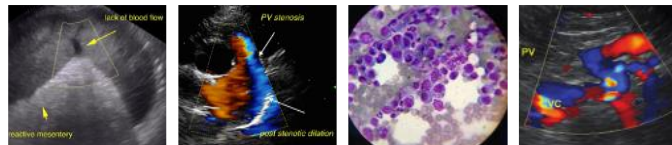
Dr. Tater

INVOICE

21810

DATE

11/1/21



PATIENT

Paige Parker

SPECIES

Canine

BREED

Mix

SEX

Female

AGE

6 years

WEIGHT

35lbs

INTERPRETED BY

Maggie Machen Lamy,
DVM, DACVIM
(Cardiology)

IMAGING PERFORMED BY

Jennifer Snyder,
Sand Hills MVU

HOSPITAL NAME

Pine Valley Animal
Hospital

REFERRING VET

Dr. Tater

INVOICE

21810

DATE

11/1/21

INTERPRETATION OF THE FINDINGS & FURTHER RECOMMENDATIONS

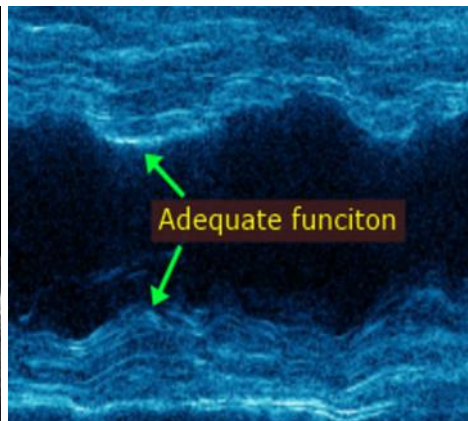
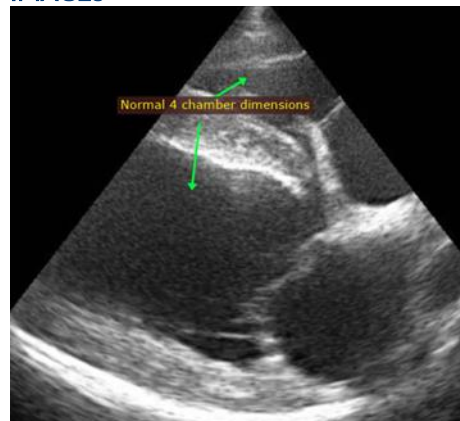
Overtly normal cardiac structure and function with no origin of the murmur identified. There is no obvious valvular regurgitation or chamber enlargement noted. No obvious evidence of pulmonary hypertension; however, this may certainly develop in the future if the cough is not controlled.

Given these findings, there is no obvious no cardiac contribution to the cough. Consider primary airway issues such as collapsing trachea, early lower airway disease, infectious/inflammatory infiltrate, etc.

No cardiac medications are indicated at this time. Monitor for development of a murmur, progressive cough, labored breathing, exercise intolerance or collapse episodes. Signs of pulmonary hypertension should also be discussed including exertional dyspnea or collapse. It is important to note that a cough is not caused by pulmonary hypertension; rather the cough is the cause of pulmonary hypertension. Adequate symptom management is important to avoid this manifestation.

A recheck echocardiogram is recommended if the murmur persists/intensifies, or other signs of cardiac disease or pulmonary hypertension develop.

IMAGES



The information and recommendations provided are based on the images presented by the referring veterinarian. No evaluation can be communicated regarding pathology that was not visible in the image/video clips provided.

Thank you for this referral. This report was generated using transcription software, and minor dictation errors may be present. If the clinical or image interpretation does not parallel your findings or if I can be of any further assistance, please contact me.

Maggie Machen Lamy, DVM
Diplomate of the American College of Veterinary Internal Medicine (Cardiology)
info@sonopath.com